

Overview

Evaluating the Fisher's technique for unilateral complete cleft lip repair: A critical literature review

Huyh Thi Le Chau¹, Tran Tan Tai^{2*}, Le Trung Chanh³, Le Van Nhat Thang²

¹Department of Inter-Specialties, Quang Ngai Obstetrics and Pediatrics Hospital

²Faculty of Odonto-stomatology, University of Medicine and Pharmacy, Hue University

³National Hospital of Odonto-Stomatology, Ho Chi Minh City, Ministry of Health

*Corresponding author: Tran Tan Tai. Email: tttai@huemed-univ.edu.vn; trantantai@hueuni.edu.vn

Received: 25/10/2025; Accepted: 20/04/2026; Published: 30/04/2026

DOI: 10.34071/jmp.2026.2.756

#Co-first authors: Tran Tan Tai

Summary

Cleft lip is a common congenital deformity that significantly affects facial aesthetics, oral function, speech development, and psychosocial well-being. Traditional surgical techniques, such as Millard's rotation-advancement and Tension-Randall's triangular flap have limitations in achieving optimal aesthetic outcomes, particularly in recreating a natural philtral column and a symmetrical nasal base. In 2005, David M. Fisher introduced the anatomical subunit approximation technique, a modification that integrates concepts from previous techniques while emphasizing alignment along aesthetic subunits of the lip. This method utilizes precise markings and measurements to design incisions that follow the natural philtral column, combined with a small superiorly based triangle (average 1.24 mm) above the cutaneous roll for optimal lengthening without distorting Cupid's bow. A laterally based vermilion flap is also employed to correct central vermilion deficiency, ensuring a continuous and harmonious vermilion border. Studies have demonstrated that Fisher's technique provides better outcomes in terms of scar camouflage, philtrum reconstruction, and nasal symmetry compared to traditional methods. However, it requires thorough anatomical knowledge and meticulous surgical planning due to its technical complexity. This review highlights the principles, surgical steps, advantages, limitations, and reported clinical outcomes of Fisher's technique for repairing unilateral complete cleft lip, emphasizing its importance as an advanced surgical approach in modern cleft care.

Keywords: *Cleft lip; unilateral cleft lip surgery; Fisher's technique.*

1. INTRODUCTION

Craniofacial congenital anomalies are the fourth most common type of birth defects found in newborns, with cleft lip and palate being the most frequent deformities affecting the head and neck region [1]. Oral clefts, encompassing cleft lip (CL), cleft palate (CP), and cleft lip and palate (CLP), represent a diverse group of non-lethal congenital anomalies with a multifactorial etiology involving both genetic predisposition and environmental influences. Because of their epidemiological and embryological similarities, cleft lip (CL) and cleft lip with palate (CLP) are often classified together under the term cleft lip with or without cleft palate (CL/P) [2]. Unilateral cleft lip is a complex congenital malformation resulting from the failure of fusion between the upper lip and nasal structures during embryonic development. This condition affects the appearance and functionality of the lip, nose, and maxilla [3]. Over the past several decades, surgical reconstructive techniques applied to unilateral cleft lip have made significant advancements, incorporating individualized treatment planning,

precise tissue handling, and meticulous operative execution. Historically, multiple methods have been devised for cleft lip repair, such as the Millard rotation-advancement technique, the Tension-Randall technique, and various triangular flap approaches [4-7]. This review summarizes contemporary concepts and highlights the Fisher's surgical technique in the management of unilateral cleft lip deformities.

2. REVIEW CONTENT

2.1. Search strategy: To conduct this review, a systematic literature search process was performed to gather evidence related to the Fisher's technique in unilateral cleft lip repair. Databases: Literature was retrieved from reputable biomedical databases, including PubMed, Google Scholar, ScienceDirect, and the Cochrane Library. Keywords: A combination of search terms was utilized, including: "Cleft lip", "unilateral cleft lip surgery", "Fisher's technique", "anatomical subunit approximation", and "surgical outcomes". Inclusion Criteria: Studies providing detailed descriptions of the Fisher's surgical

technique. Clinical studies comparing aesthetic and functional outcomes between the Fisher's technique and traditional methods such as Millard or Tennison-Randall. Articles published in English between 2005 (the inception of the Fisher's technique) and 2024. Exclusion Criteria: Articles without available full-text or with ambiguous data. Studies focusing on bilateral cleft lip or techniques not directly related to Fisher's anatomical subunit principles.

2.2. Historical Background and Classical Techniques

2.2.1. Historical Background

Introduced in 2005 by Dr. David M. Fisher in Canada, the Fisher's technique employs the anatomical subunit approximation method for cleft lip repair [8]. This technique is designed to position the surgical scar along ideal anatomical lines, thereby achieving superior aesthetic outcomes. It involves lengthening the philtral column on the medial segment of the lip via a small incision placed at the white roll, which is subsequently closed using a triangular flap from the lateral segment. The resulting suture line extends from the vermilion border, incorporates the advancement of the triangular flap, and continues up to the columellar base, curving toward the nasal base. By aligning the scar within the natural anatomical subunits, Fisher's technique ensures that the incision on the medial lip segment accurately recreates the normal philtral contour [9,10].

2.2.2. Classical Techniques

The Tennison (Tennison-Randall) technique uses a triangular flap from the lateral lip segment, which is transposed into an incision on the medial segment to increase the vertical height of the cleft side and restore the symmetry of the philtrum and Cupid's bow. This method provides good control over lip length and shape, but its main limitation is the creation of a transverse scar across the philtral area [5].

The Millard rotation-advancement technique involves creating a curved rotational incision on the medial lip segment, allowing the Cupid's bow to be rotated downward into its natural position, combined with an advancement flap from the lateral lip segment to close the defect. This method preserves the philtrum and Cupid's bow continuity, achieves good symmetry, and allows flexibility during surgery. However, it requires precise planning and execution to avoid tension, distortion, or insufficient rotation [7].

2.3. Surgical technique, Advantages and disadvantages

2.3.1. Surgical technique

The Fisher's technique is based on the "Anatomical Subunit Approximation" method; therefore, the precise identification of these 25 landmarks is critical for achieving optimal aesthetic outcomes. These points facilitate the calculation of total lip height and lesser lip height (the width of the inferior triangle) to ensure symmetry and balance for the Cupid's bow.

Fisher detailed the steps of the technique as described below [8]:

Markings and Measurements

Use 25 anatomical landmarks, as shown in Figure 1.

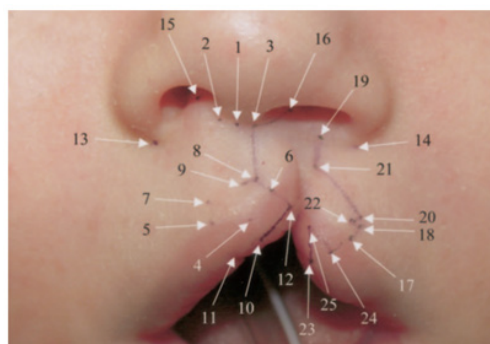


FIG.1. Key anatomical landmarks are delineated using a surgical marking pen and gentian violet [8]

(1). Midpoint of the columella base, (2). Noncleft side columella base, (3).Cleft side columella base, (4).Noncleft side Cupid's bow peak, (5). Cupid's bow low point (midpoint), (6). Cleft side Cupid's bow peak (medial), (7).Noncleft side commissure, (8). Medial segment - Upper point of philtral column, (9). Medial segment - Lower point of philtral column, (10). Medial segment - White roll landmark, (11). Medial segment - Mucocutaneous junction, (12). Medial segment - Superior triangle apex, (13). Noncleft side alar cinch point, (14). Cleft side alar cinch point, (15). Subnasale (Noncleft), (16). Subnasale (Cleft), (17). Lateral segment - Cupid's bow peak (lateral), (18).Lateral segment - White roll landmark, (19). Lateral segment - Superior point (nasal base), (20). Lateral segment - Lower point of philtral column, (21). Lateral segment - Upper point of philtral column, (22). Lateral segment - Triangle base point, (23). Lateral segment - Vermilion-cutaneous junction, (24). Lateral segment - Vermilion flap base, (25). Lateral segment - Mucosal transition poin. Measurements are taken as follows (Fig. 2):

- Vertical measurements are recorded from the base of the philtral columns at their junction with the columella-labial crease, extending superiorly to the designated landmarks positioned above the apices of Cupid's bow.

- Total lip height (a): measured with the lip at rest.
- Greater lip height (b): measured with gentle downward traction on the lip to unfurl the medial lip and predict postoperative tension.
- Lesser lip height (c): calculated as total lip height - greater lip height - 1 mm (it usually ranges from 1 to 1.5 mm and should be kept below 2 mm).

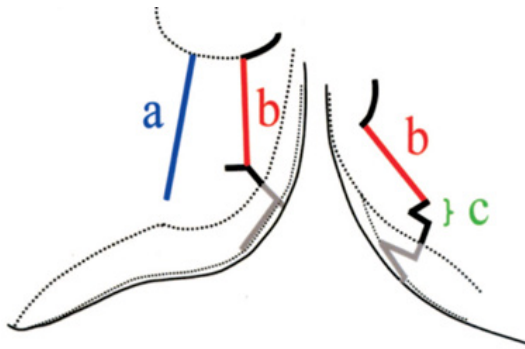


FIG.2. Calculation of lesser lip height (c) in the Fisher technique: schematic illustration of total height (a), greater height (b), and base width of inferior triangle (c) [8]

Incisions and Dissection:

- Incisions are made along the anatomical subunit boundaries for optimal aesthetic scar placement.
- Medial lip: a perpendicular incision is made above Cupid’s bow, with a small superior triangle (average 1.24 mm) for lengthening.
- Lateral lip: the incision is designed to match vermilion height; a lateral vermilion flap is created to fill the central vermilion deficiency.

Muscle Release and Repair

- The orbicularis oris muscle is freed from abnormal insertions and reapproximated anatomically.
- For complete clefts, an inferior turbinate flap is used to cover mucosal defects at the alveolar cleft.

Nasal Repair

- The vestibular web is released and an alar base cinch stitch is performed to centralize and level the nasal base.

- Internal nasal valve plication sutures are placed to maintain lateral crus positioning.

Closure

- Sequential closure of the mucosa, muscle, and skin layers is performed.
- The lateral vermilion flap is inset into the medial opening incision to restore a continuous vermilion border.
- The skin is sutured with 7 - 0 Prolene, lip sutures are removed after 5 - 7 days.
- Infants are allowed to feed immediately postoperatively and elbow splints are maintained for 2 weeks.

2.3.2. Advantages and disadvantages

The Fisher’s technique offers superior aesthetic outcomes by placing scars along natural anatomical subunit borders, resulting in minimal visible scarring. Consequently, lip and nasal symmetry are enhanced, ensuring accurate vermilion continuity and the creation of a well-defined Cupid’s bow. The method employs precise measurements based on 25 anatomical landmarks, resulting in predictable and balanced surgical outcomes. Additionally, it avoids scarring at the nasal base and columella, maintains the natural lip-columella fold, and features a continuous incision line without a T-point, thereby reducing the risk of conspicuous scars. Studies have reported higher Steffensen grading scores for the Fisher technique compared with the Millard technique, with a greater percentage of “good” results [8], [11-12].

However, the Fisher’s technique is technically demanding, requiring advanced surgical skills, comprehensive anatomical knowledge, and meticulous preoperative planning. The identification of 25 anatomical landmarks increases the preparation time. Inaccurate measurements may result in an excessively long triangular flap. Furthermore, unlike the Millard technique, the Fisher’s technique lacks intraoperative flexibility, making real-time adjustments more challenging [7], [11].

2.4. Outcomes and evidence

The clinical outcomes and comparative evidence of Fisher’s technique across various studies are summarized in Summary table.

Author (Year)	Study Design/Sample	Comparison	Key Findings & Outcomes
Hoffmann & Dyleram (2011)	2.5-year follow-up study	Millard vs. Fisher	Fisher’s technique showed superior aesthetic results, specifically in Cupid’s bow symmetry and natural vermilion border contour.
Swanson et al. (2021)	Case series (53 cases) in Melbourne (2008-2012)	Fisher technique implementation	Viewed as an evolution of earlier methods; yielded excellent postoperative symmetry of the lip and nose with natural facial outcomes.

Suchyta et al. (2020)	Online crowdsourcing (1,300+ participants)	Millard, Fisher, Mohler, and Noordhoff	Fisher's technique achieved the highest aesthetic scores for natural appearance and symmetry with statistical significance.
Saeed et al. (2023)	Clinical outcome evaluation	Fisher technique	Fisher's method provides more predictable clinical outcomes due to highly precise measurements.
Fisher (2005)	Original technique description	Fisher vs. Millard	Reported higher Steffensen grading scores for the Fisher's technique compared to the Millard's technique

The study by Hoffmann D and Dyleram D (2011) compared the Millard rotation-advancement technique and Fisher's anatomical subunit approximation technique for unilateral cleft lip repair over a 2.5-year follow-up period. The outcomes were evaluated based on Cupid's bow symmetry, nasal form, vermilion border alignment, hypertrophic or discolored scarring, and suture marks. The results demonstrated that while both techniques achieved satisfactory functional outcomes, Fisher's technique showed superior aesthetic results. Specifically, Fisher's method provided a more defined and symmetric Cupid's bow, a natural vermilion border contour, and minimized hypertrophic or discolored scarring, leading to a more harmonious and balanced nasolabial appearance compared with Millard's technique. Thus, the study concluded that Fisher's technique is preferable, as it optimally combines functional restoration with superior aesthetic refinement across all evaluated parameters, making it particularly suitable for long-term cleft lip reconstruction goals [13].

From 2008 to 2012 in Melbourne, Australia, Jordan W. Swanson and his team implemented the Fisher anatomical subunit repair technique in 53 unilateral cleft lip cases. They considered Fisher's approach to be an evolution and refinement of earlier methods developed by Thompson, Tennison, and Millard. By segmenting the lip into distinct aesthetic subunits, accurately identifying critical anatomical landmarks, and performing thorough release of the orbicularis oris muscle along with nasal base adjustments, this technique yielded excellent postoperative symmetry of the lip and nose, providing patients with highly natural and harmonious facial outcomes [14].

Suchyta et al. (2020) conducted a study employing online crowdsourcing through Amazon Mechanical Turk to assess the aesthetic results of various unilateral cleft lip repair techniques- namely, Millard, Fisher, Mohler, and Noordhoff. Over 1,300

lay participants evaluated 44 patient images before and after surgery, rating them based on factors such as natural appearance, symmetry, and overall facial harmony. Findings indicated that the Fisher's technique achieved the highest aesthetic scores, followed by Mohler, Millard, and Noordhoff, with statistically significant superiority for Fisher. This research demonstrates that crowdsourcing provides a practical, scalable, and cost-effective approach for evaluating aesthetic outcomes in plastic and reconstructive surgery by incorporating public perception into surgical outcome assessment [15,16].

Fisher's technique divides the cleft into two distinct anatomical units: the nasal component (including the nasal base and alar rim) and the lip component (comprising the white roll, vermilion, and philtral dimple). It utilizes highly precise measurements to ensure consistent dimensions of each anatomical unit both before and after surgery. As a result, the clinical outcomes of Fisher's method are generally more predictable [8], [12], [16]. This technique creates scar tissue precisely along anatomical landmarks, extending from the peak of the Cupid's bow up to the nasal base, with scars well concealed beneath the columella base and within the white roll. However, compared with Millard's approach, Fisher's technique is more complex, requiring up to 25 surgical reference points during the procedure [17-19].

3. CONCLUSIONS

Fisher's technique offers superior aesthetic outcomes in unilateral cleft lip repair by aligning scars along natural anatomical landmarks, thereby enhancing philtral reconstruction and nasal symmetry. Although it is more complex and requires precise markings, the technique provides predictable, harmonious outcomes, making it a preferred modern approach despite its technical demands.

REFERENCES

1. Bernheim N, Georges M, Malevez C, De Mey A, Mansbach A. Embryology and epidemiology of cleft lip and palate. *B-ENT*. 2006;2(4):11–9.
2. Allam E, Windsor LJ, Stone C. Cleft Lip and Palate: Etiology, Epidemiology, Preventive and Intervention Strategies, *Anat Physiol*, 2014, 4(3), 1-6.
3. Oh TS, Kim YC. A comprehensive review of surgical techniques in unilateral cleft lip repair. *Arch Craniofac Surg*. 2023;24(3):91–104.
4. Randall P. A triangular flap operation for the primary repair of unilateral clefts of the lip. *Plast Reconstr Surg*. 1959;23(4):331–40.
5. Tennison CW. The repair of the unilateral cleft lip by the stencil method. *Plast Reconstr Surg*. 1952;9(2):115–20.
6. Cronin TD. A modification of the Tennison-type lip repair. *Cleft Palate J*. 1966;3:376–82.
7. Millard DR. Rotation advancement principle in cleft lip closure. *Cleft Palate J*. 1964;12:246–52.
8. Fisher DM. Unilateral cleft lip repair: an anatomical subunit approximation technique. *Plast Reconstr Surg*. 2005;116(1):61–71.
9. Marcus JR, Allori AC, Santiago PE. Principles of cleft lip repair: conventions, commonalities, and controversies. *Plast Reconstr Surg*. 2017;139(3):764e–773e.
10. Mittermiller PA, Martin S, Johns DN, Perrault D, Jablonka EM, Khosla RK. Improvements in cleft lip aesthetics with the Fisher repair compared to the Mohler repair. *Plast Reconstr Surg Glob Open*. 2020;8(6):e2919.
11. Pradnyandari NKPD. Aesthetic outcome comparison between Millard and Fisher technique for cleft lip surgery: a literature review. *Int J Biosci*. 2023;17(2):153–9.
12. Saeed S, Khan FA, Jan SN, Shakeel Z, Bilal B, Bashir MM. Outcomes of Fisher technique for unilateral incomplete cleft lip repair. *Ann King Edward Med Univ*. 2023;29(2):129–35.
13. Hoffman D, Dyleram D. Comparison of the Millard and Fisher technique for closure of the unilateral cleft lip. *Int J Oral Maxillofac Surg*. 2011;40(10):e14.
14. Swanson JW, Van Slyke AC, Chong DK. Principalization of the anatomical subunit approximation technique of unilateral cleft lip repair. *Face (Basel)*. 2021;2(3):225–35.
15. Suchyta M, Azad A, Patel AA, Khosla RK, Lorenz HP, Nazerali RS. Applied online crowdsourcing in plastic and reconstructive surgery: a comparison of aesthetic outcomes in unilateral cleft lip repair techniques. *Ann Plast Surg*. 2020;84(5 Suppl):S307–13.
16. Deshmukh M, Vaidya S, Deshpande G, Galinde J, Natarajan S. Comparative Evaluation of Esthetic Outcomes in Unilateral Cleft Lip Repair Between the Mohler and Fisher Repair Techniques: A Prospective, Randomized, Observer-Blind Study, *J Oral Maxillofac Surg*, 2019, 77(1), 182e1-182e8.
17. Gaber A, Saied S, Ali AA. Comparative study between Mohler (modified Millard) and Fisher techniques in unilateral cleft lip repair. *SVU Int J Med Sci*. 2023;6(1):435–49.
18. Elbanoby TM, Abdelfattah IHH, Yousif SH. Comparison of the Fisher anatomical subunit and modified Millard rotation advancement cleft lip repairs: a systematic review. *Al-Azhar Int Med J*. 2024;5(6):55–60.
19. ElMaghraby MF, Ghozlan NA, Ashry MH, Abouarab MH, Farouk A. Comparative study between Fisher anatomical subunit approximation technique and Millard rotation-advancement technique in unilateral cleft lip repair. *Alexandria J Med*. 2021;57(1):92–102.